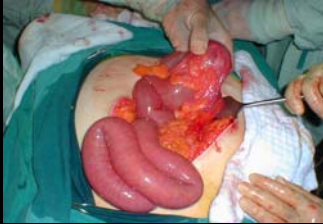

INTESTINAL OBSTRUCTION



Dr.Yunus Yavuz

Intestinal obstruction

1. Definition
2. Sites of obstruction
 - Small bowel
 - Large bowel
3. Causes of the obstruction
 - Lesions extrinsic to the bowel wall
 - Lesions intrinsic to the bowel wall
 - Intraluminal obturator lesions
4. Types of intestinal obstruction
 - Mechanical obstruction vs. Adynamic ileus
 - Partial vs. Complete
 - Simple vs. Strangulated
 - High vs. low
 - Small bowel vs colon
5. Clinical picture
 - Radiological tests
 - Fluid and electrolyte status
6. Treatment of intestinal obstruction

1. Definition

INTERRUPTION IN THE PASSAGE OF
INTESTINAL CONTENTS

Intestinal obstruction

1. Definition
2. Sites of obstruction
 - Small bowel
 - Large bowel
3. Causes of the obstruction
 - Lesions extrinsic to the bowel wall
 - Lesions intrinsic to the bowel wall
 - Intraluminal obturator lesions
4. Types of intestinal obstruction
 - Mechanical obstruction vs. Adynamic ileus
 - Partial vs. Complete
 - Simple vs. Strangulated
 - High vs. low
 - Small bowel vs colon
5. Clinical picture
 - Radiological tests
 - Fluid and electrolyte status
6. Treatment of intestinal obstruction

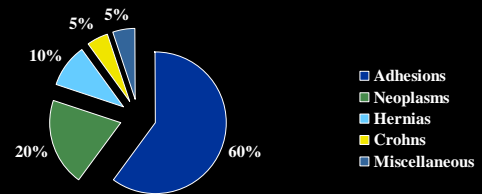
2. Sites of obstruction

Small Bowel vs. Large Bowel

- Scenario
 - prior operations, change in bowel habits
- Clinical picture
 - scars, masses/ hernias, amount of distension/ vomiting
- Radiological studies
 - gas in colon?, volvulus?, transition point, mass
- (Almost) always operate on LBO, often treat SBO non-operatively

2. Sites of obstruction

Common Causes of Small Bowel Obstruction (SBO)



2. Sites of obstruction

Common Causes of Large Bowel Obstruction (LBO)

- Colon cancer
- Diverticulitis
- Volvulus
- Hernia

↑
frequency

Unlike SBO, adhesions very unlikely to produce LBO

Intestinal obstruction

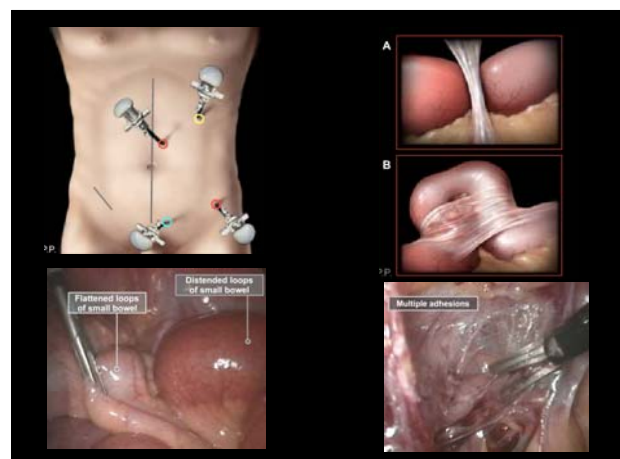
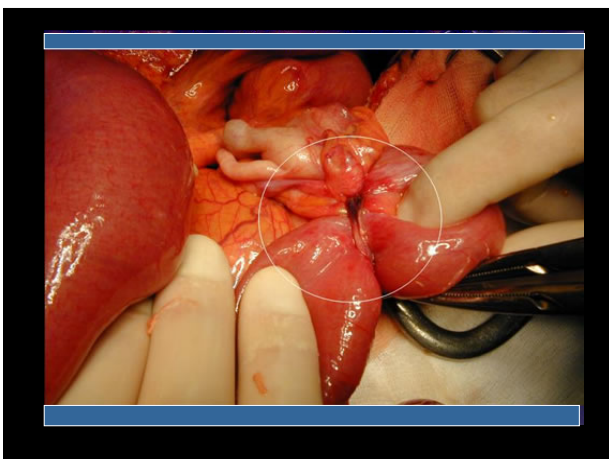
1. Definition
2. Sites of obstruction
 - Small bowel
 - Large bowel
3. **Causes of the obstruction**
 - Lesions extrinsic to the bowel wall
 - Lesions intrinsic to the bowel wall
 - Intraluminal obturator lesions
4. Types of intestinal obstruction
 - Mechanical obstruction vs. Adynamic ileus
 - Partial vs. Complete
 - Simple vs. Strangulated
 - High vs low
 - Small bowel vs colon
5. Clinical picture
 - Radiological tests
 - Fluid and electrolyte status
5. Treatment of intestinal obstruction

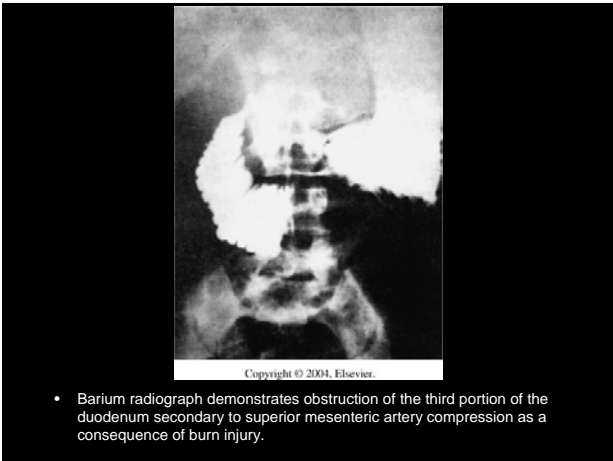
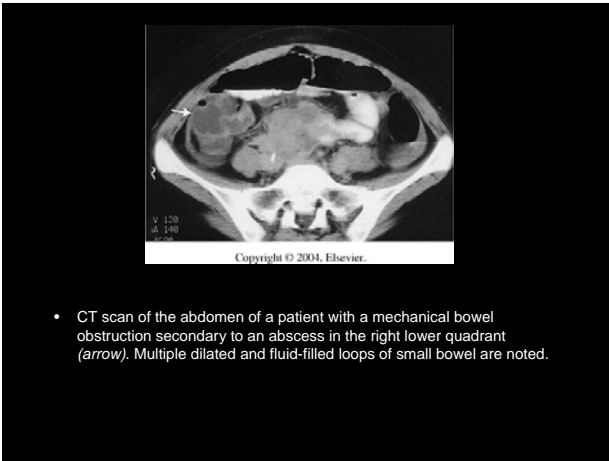
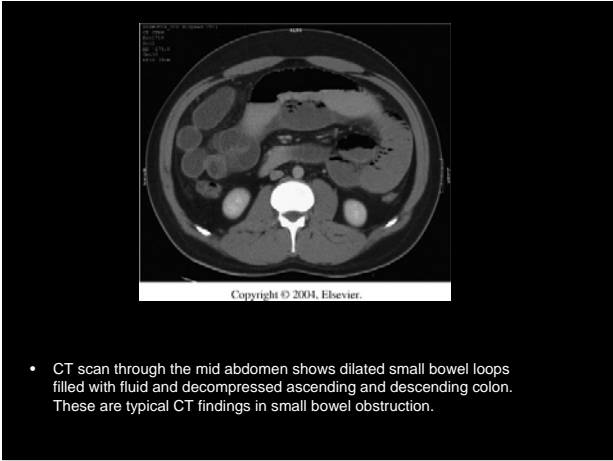
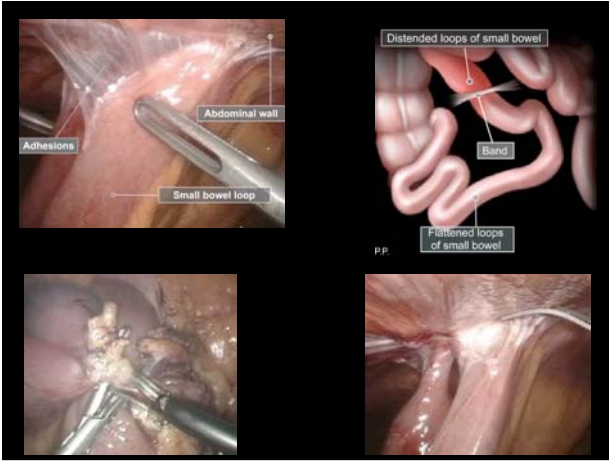
3. Causes of obstruction

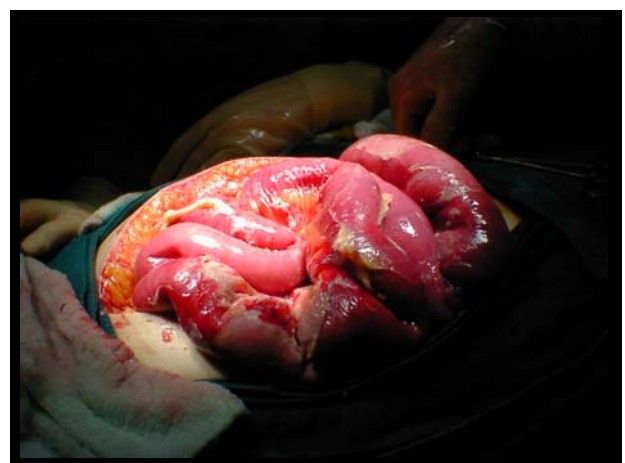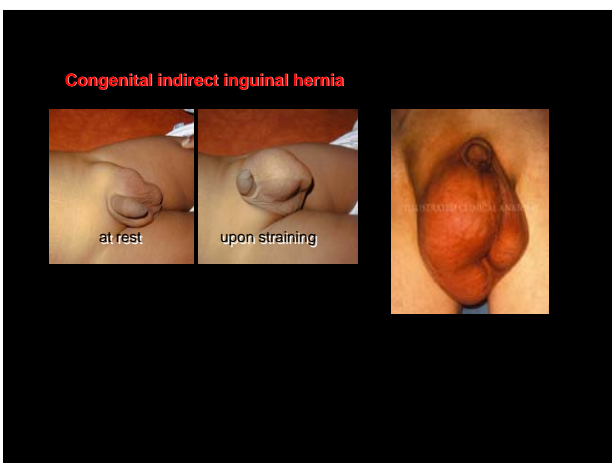
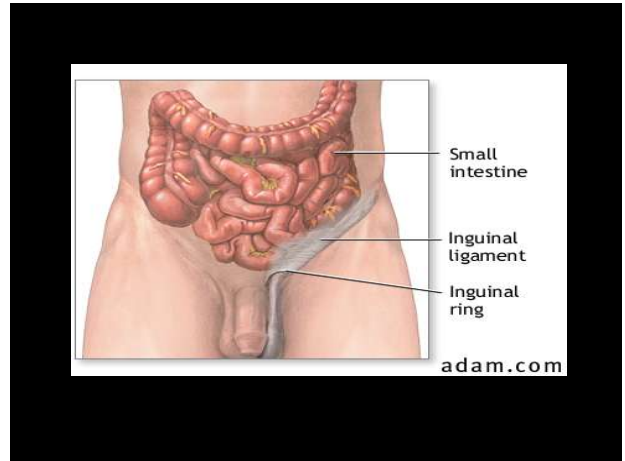
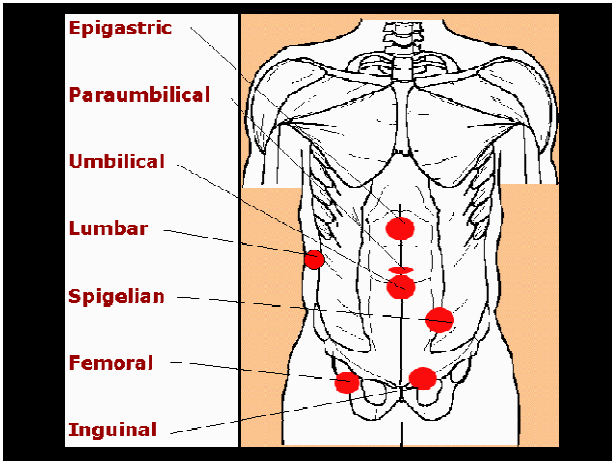
- Outside the wall
- Inside the wall
- Inside the lumen

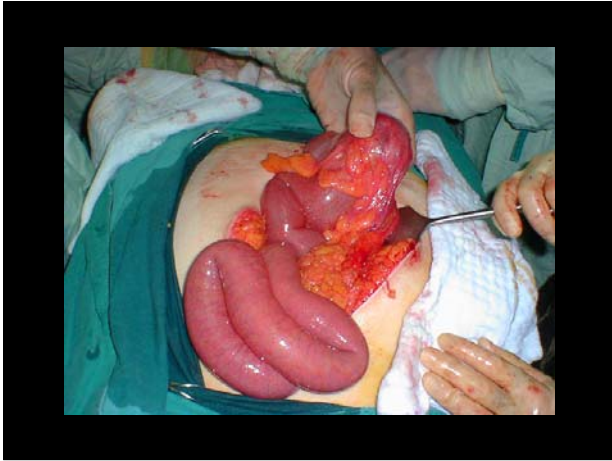3. Causes of obstruction Lesions Extrinsic to Intestinal Wall

- Adhesions (usually postoperative)
- Hernia
 - External (e.g., inguinal, femoral, umbilical, or ventral hernias)
 - Internal (e.g., congenital defects such as paraduodenal, foramen of Winslow, and diaphragmatic hernias or postoperative secondary to mesenteric defects)
- Neoplastic
 - Carcinomatosis, extraintestinal neoplasm
- Intra-abdominal abscess/ diverticulitis
- Volvulus (sigmoid, cecal)









3. Causes of obstruction Lesions Intrinsic to Intestinal Wall

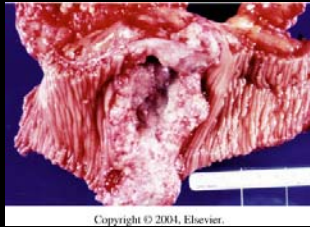- Congenital
 - Malrotation
 - Duplications/cysts
- Traumatic
 - Hematoma
 - Ischemic stricture
- Infections
 - Tuberculosis
 - Actinomycosis
 - Diverticulitis
- Neoplastic
 - Primary neoplasms
 - Metastatic neoplasms
- Inflammatory
 - Crohn's disease
- Miscellaneous
 - Intussusception
 - Endometriosis
 - Radiation enteropathy/stricture

• CT scan of a patient with Crohn's disease demonstrates marked thickening of the bowel (*arrows*) with a high-grade partial small bowel obstruction and dilated proximal intestine.

Resection of the ileum, ileocecal valve, cecum, and ascending colon for Crohn's disease of the ileum. Intestinal continuity is restored by end-to-end anastomosis.

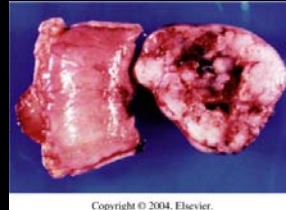
Barium radiograph demonstrates a typical "apple-core" lesion (*arrows*) caused by adenocarcinoma of the small bowel, producing a partial obstruction with dilated proximal bowel.

CT scan of abdomen demonstrates a small bowel neoplasm (*arrow*).



Copyright © 2004, Elsevier.

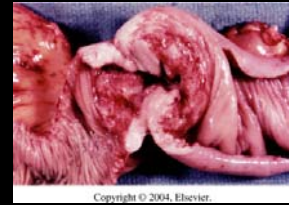- Large circumferential mucinous adenocarcinoma of the jejunum.



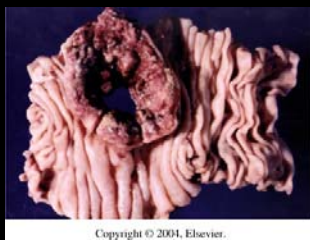
Copyright © 2004, Elsevier.

Small bowel leiomyosarcoma (malignant gastrointestinal stromal tumor) with hemorrhagic necrosis.

Gross photograph of primary lymphoma of the ileum shows replacement of all layers of the bowel wall with tumor.

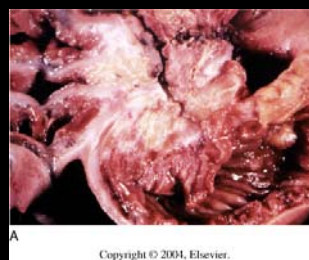

Copyright © 2004, Elsevier.



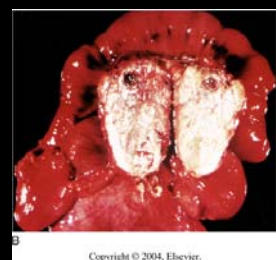Copyright © 2004, Elsevier.

Small bowel lymphoma presents as perforation and peritonitis.



A

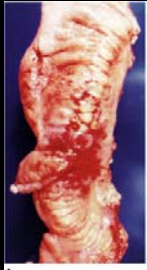Copyright © 2004, Elsevier.



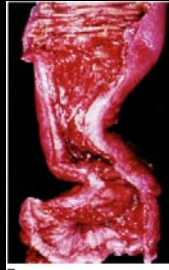
B

Copyright © 2004, Elsevier.

- Gross pathologic characteristics of carcinoid tumor. A, Carcinoid tumor of the distal ileum demonstrates the intense desmoplastic reaction and fibrosis of the bowel wall. B, Mesenteric metastases from a carcinoid tumor of the small bowel.

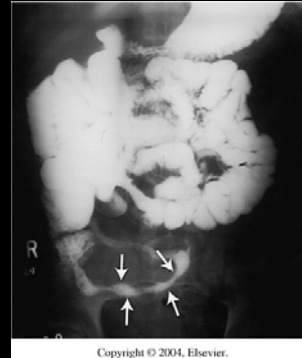


A
Copyright © 2004, Elsevier.



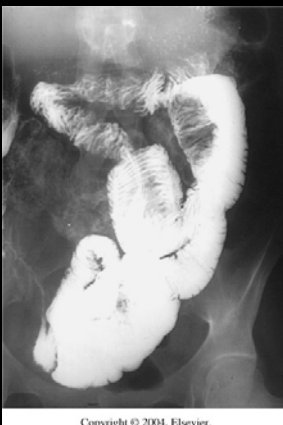
B
Copyright © 2004, Elsevier.

- Gross pathologic features of Crohn's disease. **A**, Serosal surface demonstrates extensive "fat wrapping" and inflammation. **B**, Resected specimen demonstrates marked fibrosis of the intestinal wall, stricture, and segmental mucosal inflammation.



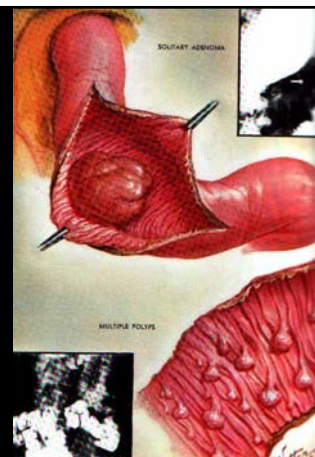
Copyright © 2004, Elsevier.

- Small bowel series in a patient with Crohn's disease demonstrates a narrowed distal ileum (*arrows*) secondary to chronic inflammation and fibrosis.



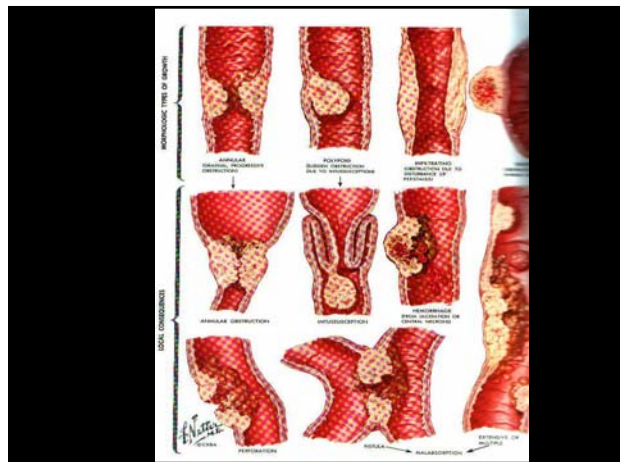
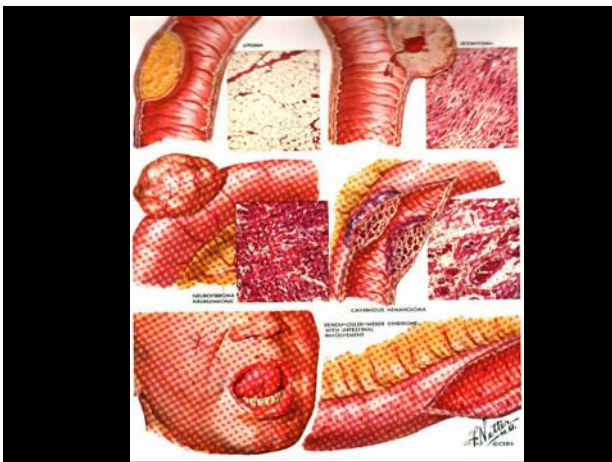
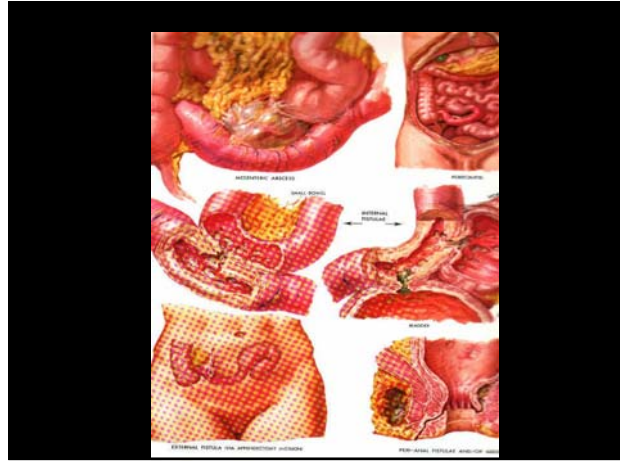
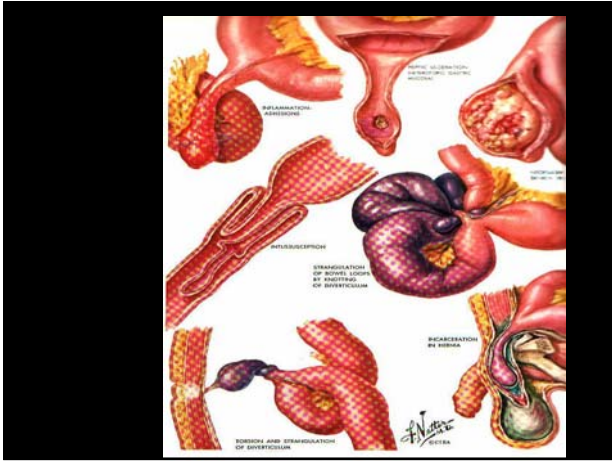
Copyright © 2004, Elsevier.

- Barium study demonstrates jejunojejunal intussusception.



SOLITARY ADENOMA

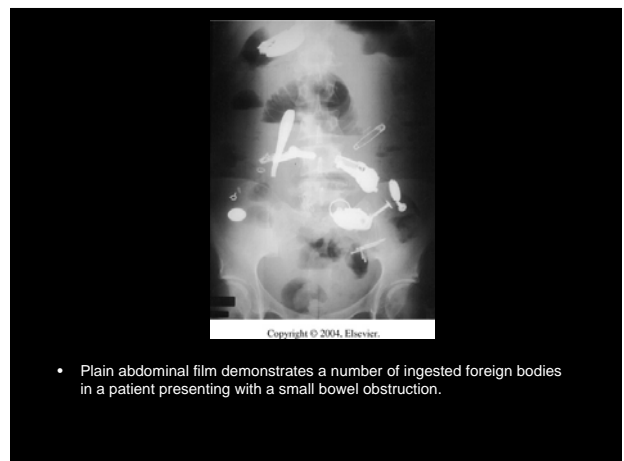
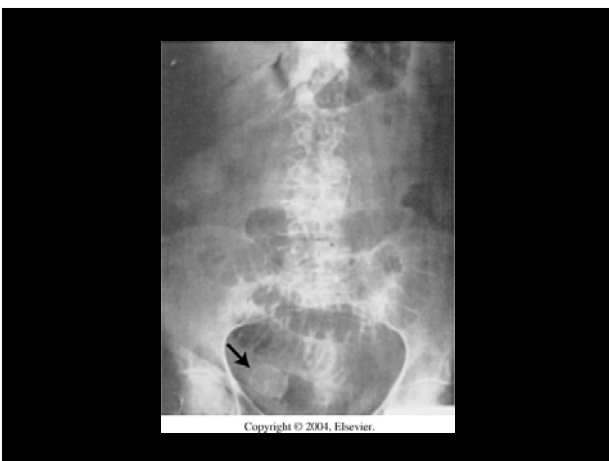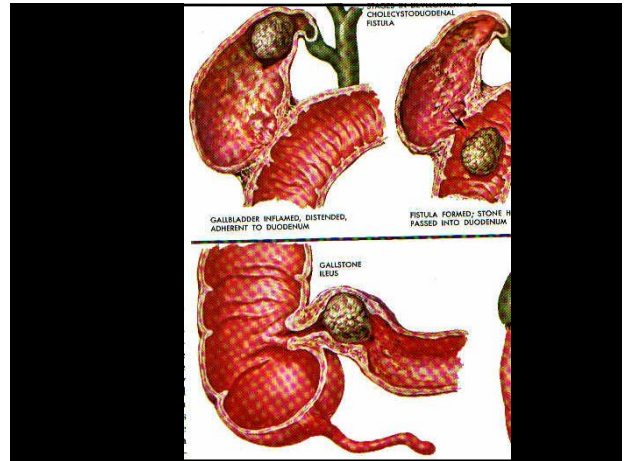
MULTIPLE POLYPS



3. Causes of obstruction

Intraluminal/ Obturator Lesions

- Gallstone
- Enterolith
- Bezoar
- Foreign body



- Plain abdominal film demonstrates a number of ingested foreign bodies in a patient presenting with a small bowel obstruction.

Intestinal obstruction

1. Definition
2. Sites of obstruction
 - Small bowel
 - Large bowel
3. Causes of the obstruction
 - Lesions extrinsic to the bowel wall
 - Lesions intrinsic to the bowel wall
 - Intraluminal obturator lesions
4. **Types of intestinal obstruction**
 - Mechanical obstruction vs. Adynamic ileus
 - Partial vs. Complete
 - Simple vs. Strangulated
 - High vs low
 - Small bowel vs. colon
5. Clinical picture
 - Radiological tests
 - Fluid and electrolyte status
6. Treatment of intestinal obstruction

4. Types of bowel obstruction

Adynamic Ileus vs Mechanical Obstruction

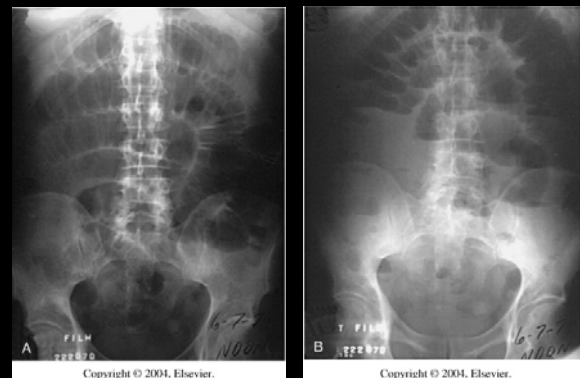- | | |
|--|---|
| <ul style="list-style-type: none"> • Gas diffusely through intestine, incl. colon • May have large diffuse A/F levels • Quiet abdomen • No obvious transition point on contrast study • Peritoneal exudate if peritonitis | <ul style="list-style-type: none"> • Large small intestinal loops, less in colon • Definite ladder A/F levels • "Tinkling", quiet= late • Obvious transition point on contrast study • No peritoneal exudate |
|--|---|

4. Types of bowel obstruction

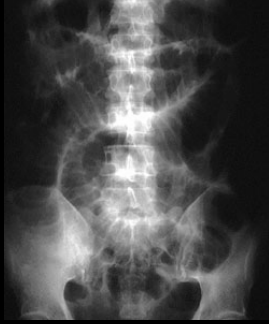Causes of Adynamic Ileus

- Following celiotomy
 - small bowel- 24h, stomach- 48h, colon- 3-5d
- Inflammation e.g. appendicitis, pancreatitis
- Retroperitoneal disorders e.g. ureter, spine, blood
- Thoracic conditions e.g. pneumonia, # ribs
- Systemic disorders e.g. sepsis, hyponatremia, hypokalemia, hypomagnesemia
- Drugs e.g opiates, Ca-channel blockers, psychotropics

Mechanical Obstruction



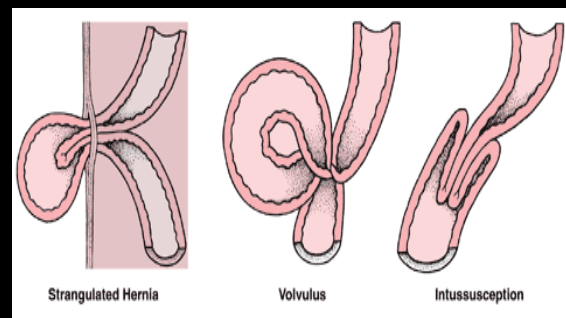
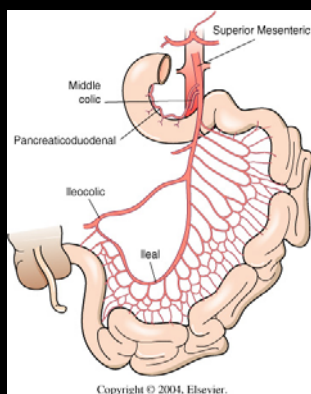
Adynamic Ileus

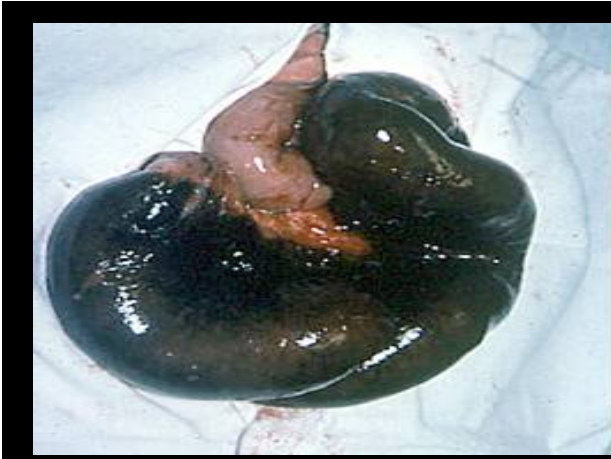

4. Types of bowel obstruction

Is there strangulation?

- 4 Cardinal Signs
fever, tachycardia, localized abdominal tenderness, leucocytosis
- 0/4 0% strangulated bowel
- 1/4 7% “ “
- 2-3/4 24% “ “
- 4/4 67% “ “
- process accelerated with closed-loop obstruction.





4. Types of bowel obstruction

Partial vs Complete

- | | | |
|--|----|--|
| <ul style="list-style-type: none"> • Flatus • Residual colonic gas above peritoneal reflection • Adhesions • 60-80% resolve with non-operative Mx • Must show objective improvement, if none by 48h consider OR | vs | <ul style="list-style-type: none"> • Complete obstipation • No residual colonic gas on AXR • SBFT may differentiate early complete from high-grade partial • Almost all should be operated on within 24h |
|--|----|--|

4. Types of bowel obstruction

Characteristics of proximal and distal small bowel obstruction

Proximal

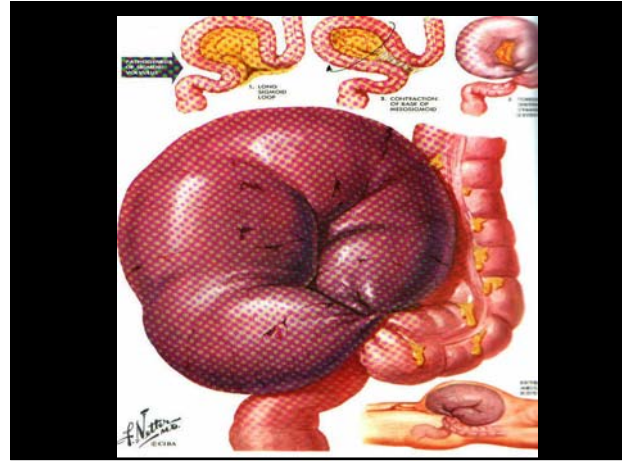
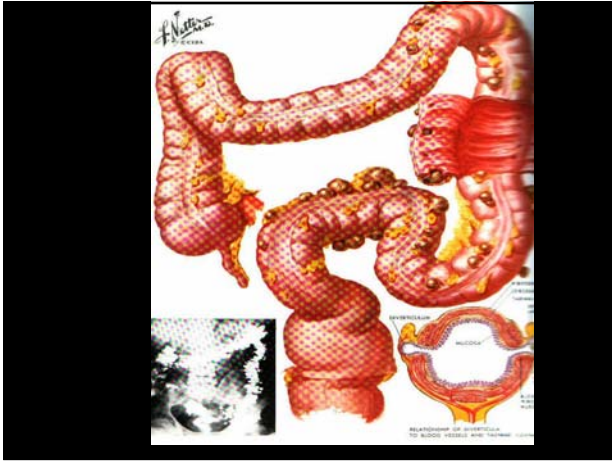
Acute onset
 Vomiting prominent
 Vomiting not feculent
 Pain at frequent intervals
 Distention minimal

Distal

Less acute onset
 Less prominent
 Often feculent
 Less frequent intervals
 Noticable

CAUSES OF COLONIC OBSTRUCTION IN ADULTS

Carcinoma	(65 %)
Diverticulitis	(20 %)
Volvulus	(5 %)
Others	(10 %)



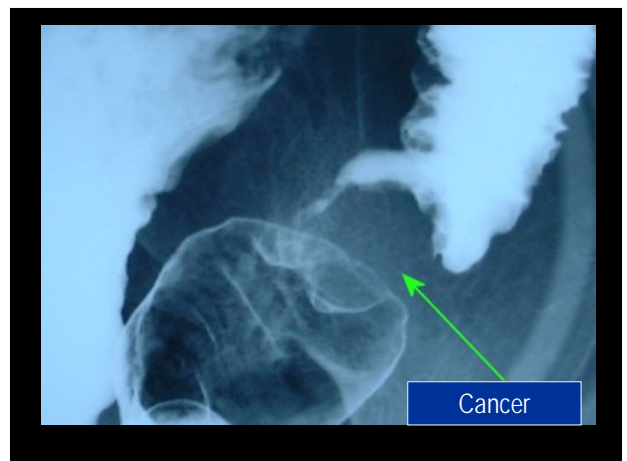
CLINICAL MANIFESTATIONS OF COLORECTAL CANCER

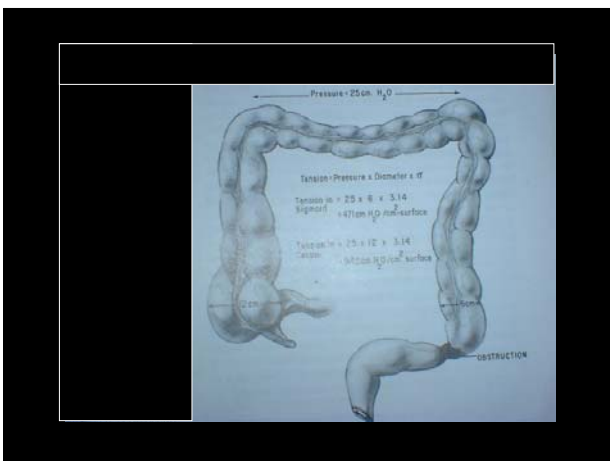
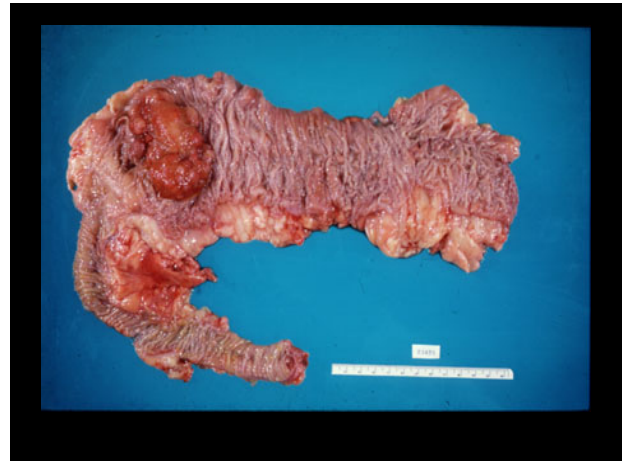
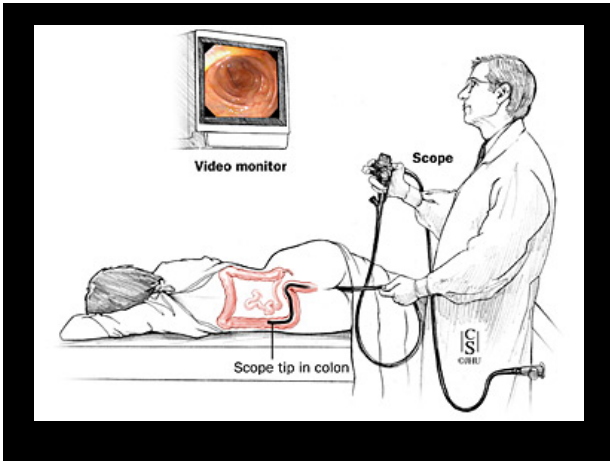
Right Colon

Anemia
Weight loss
Palpable mass
Fatigue

Left Colon

Obstructive symptoms
Gross blood in stool
Change in bowel habits
Characteristic x-ray
+sigmoidoscopy





- COLONIC OBSTRUCTION**
ESSENTIALS OF DIAGNOSIS
- Constipation-obstipation
 - Abdominal distention- sometimes tenderness
 - Abdominal pain
 - Nausea and vomiting (late)
 - Characteristic x-ray findings

Intestinal obstruction

1. Definition
2. Sites of obstruction
 - Small bowel
 - Large bowel
3. Causes of the obstruction
 - Lesions extrinsic to the bowel wall
 - Lesions intrinsic to the bowel wall
 - Intraluminal obturator lesions
4. Types of intestinal obstruction
 - Mechanical obstruction vs. Adynamic ileus
 - Partial vs. Complete
 - Simple vs. Strangulated
 - High vs low
 - Small bowel vs colon
5. **Clinical picture**
 - Symptoms and signs
 - Radiological tests
5. Treatment of intestinal obstruction

5. Clinical picture

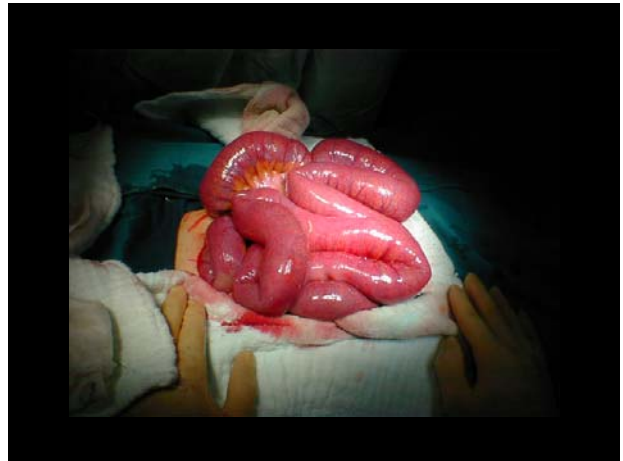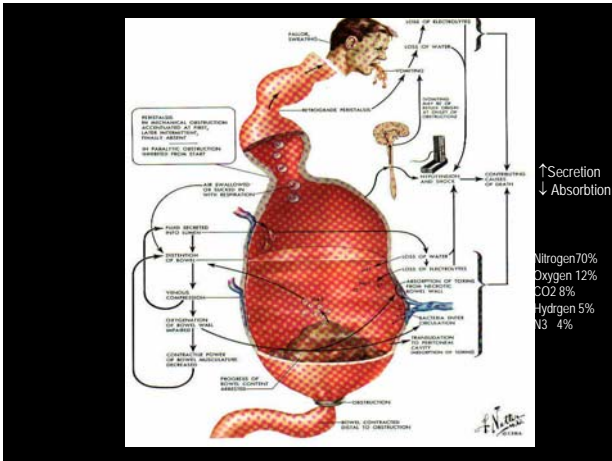
- Colicky abdominal pain
- Abdominal distension
- Vomiting
- Decreased passage of stool or flatus
- Typical radiographic picture
 - plain AXR, contrast CT, UGI/SBFT, enteroclysis

Pathophysiology

- Hypercontractility--hypocontractility
- Massive third space losses
 - oliguria, hypotension, hemoconcentration
- Electrolyte depletion
- bowel distension--increased intraluminal pressure--impedement in venous return--arterial insufficiency

LOSS OF FLUID AND ELECTROLYTES IN INTESTINAL OBSTRUCTION

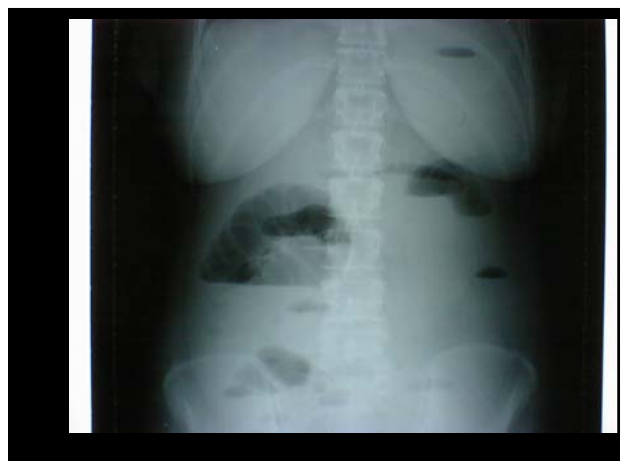- into the bowel lumen
- into the edematous bowel wall
- into the peritoneum
- vomiting or NG suction

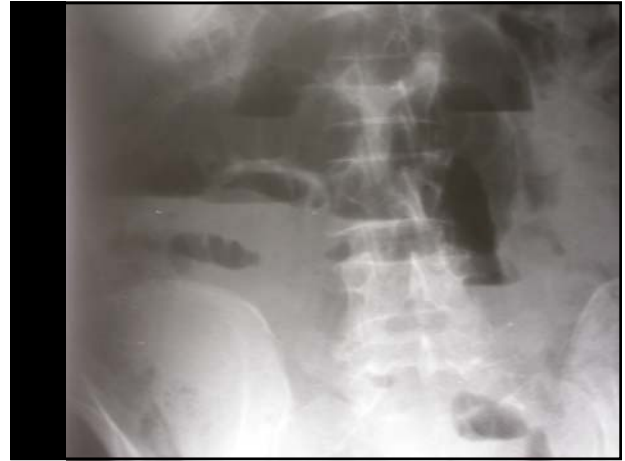
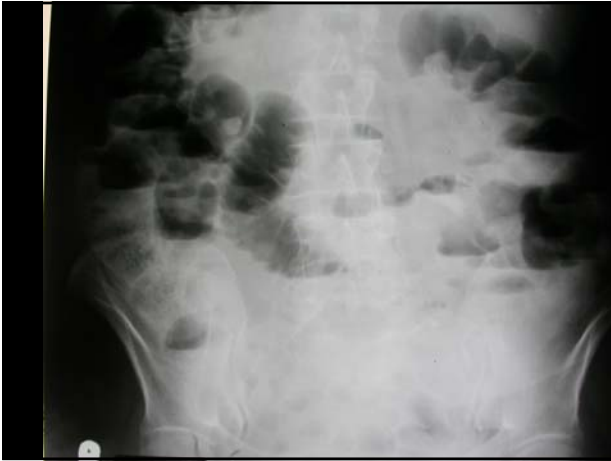
Physical findings:
Tachycardia
Rebound (+)
Muscle guarding Localised tenderness
Fever

Auscultation: High-pitched amphoric rushes
(metallic bowel sounds)

Lab: Hyponatremia, Hypochloremia, ↑ urine osm.
met. asc. Leukocytosis (15-25.000/mm³)





Intestinal obstruction

1. Definition
2. Sites of obstruction
 - Small bowel
 - Large bowel
3. Causes of the obstruction
 - Lesions extrinsic to the bowel wall
 - Lesions intrinsic to the bowel wall
 - Intraluminal obturator lesions
4. Types of intestinal obstruction
 - Mechanical obstruction vs. Adynamic ileus
 - Partial vs. Complete
 - Simple vs. Strangulated
5. Clinical picture
 - Radiological tests
 - Fluid and electrolyte status
6. **Treatment of intestinal obstruction**

Management of Bowel Obstruction

**NEVER LET THE SUN RISE OR FALL
ON A PATIENT WITH
BOWEL OBSTRUCTION**

Principles

- Fluid resuscitation
- Electrolyte, acid-base correction
- Close monitoring
 - foley, central line
- NGT decompression
- Antibiotics controversial
- TO OPERATE OR NOT TO OPERATE

SURGICAL TREATMENT

- Preoperative preparation ⇒ Partial-complete
Malignant –benign
Early posoperative
- Nasogastric suction+CVP+Foley Cath.
- Fluid and electrolyte resuscitation (Ringer
lactate+ Saline+ K (?)+ ANTIBIOTICS (?))
- Operative therapy Adhesiolysis, enterotomy, resection,
by-pass, ostomy